

The CABMM's Professor Dr Brigitte von Rechenberg and her fellow researchers outline their studies into transcutaneous drug delivery using a novel transdermal application technology

# Transcutaneous drug delivery

**C**hronic deep wounds and chronic joint disease are always a problem for patients due to the constant pain and restrictions in daily living, for both people and animals. Chronic wounds may prove difficult to heal for many reasons. Among them one of the major inhibitions is scarce distribution of drugs to wound beds and edges due to excess fibrosis and scar formation. Missing vascularity, often alongside chronic infection within the scar tissue, is just one of the major underlying problems.

Hyaline cartilage damage within the joint, often resulting from synovial membrane inflammation or small lesions, will worsen over time and result in irreversible changes. Matrix destruction is the end-result for both chronic inflammation and small lesions. In both cases, matrix-degrading enzymes such as metalloproteinases, aggrecanases, hyaluronidases and cathepsins are triggered by inflammatory mediators (nitric oxide (NO), prostaglandin (PGE<sub>2</sub>)) and cytokines (interleukins (IL1, IL6) and tumour necrosis factor) and will finally degrade the collagen network and proteoglycans, thus changing the hydro-osmotic pressure of the hyaline cartilage. It is then only a question of time until fibrillation of the cartilage surface occurs, followed by fissures and cleft formation down to the subchondral bone plate. Erosion of cartilage down to the subchondral bone is the devastating result for patients, at which point stronger

Fig. 2 Valeoskin scaffold



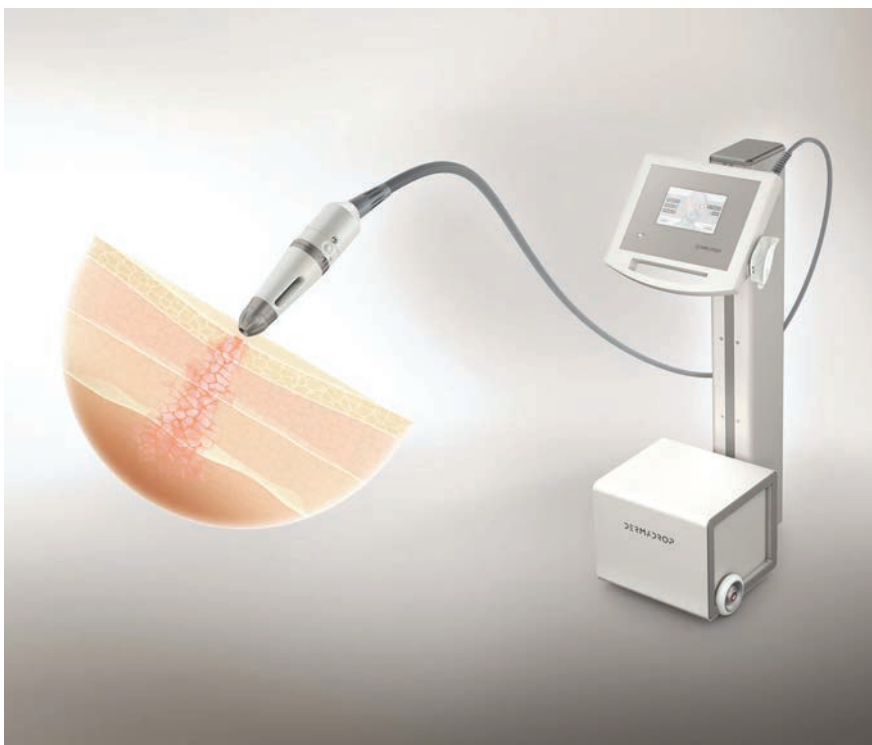
measures of therapy such as joint replacements through full or partial prosthesis may become necessary.

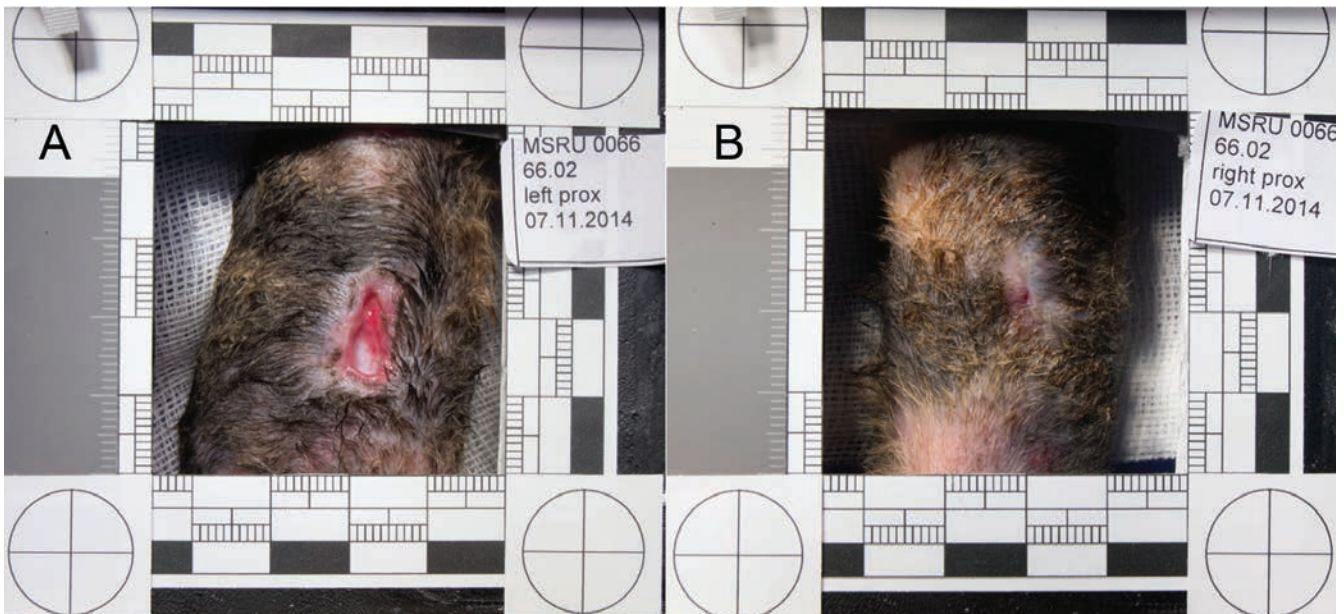
Although research in this field of osteoarthritis is extensive and has elucidated many important mechanisms about how the homeostasis of the hyaline cartilage is imbalanced, it is not yet possible to stop the degenerative processes, nor can full regeneration of the cartilage surface be achieved. Chondroprotective supplements or anti-inflammatory drugs can partially slow down the mechanism and take some of the pain away. Some approaches have engaged in cell-based therapies, but even these cannot fully restore joint integrity. Like in chronic wounds, one of the major problems in joint disease is also the local distribution of medication and keeping a therapeutic drug level over a longer period of time in the affected tissues.

Although non-steroidal anti-inflammatory drugs (NSAID) or cortison derivatives may decrease the degree of chronic inflammation and pain, they cannot put a halt to the degradation process. In contrast, NSAIDs may dose-dependently accelerate the activity of metalloproteinases and cortison derivatives may completely inhibit the synthesis of new macromolecules. Furthermore, chronic systemic application of NSAIDs and particularly cortison derivatives may cause complications, such as gastric ulcers, liver and kidney failures.

For both deep wound infections and joint diseases, alternative and innovative drug

Fig. 1 MedDrop device





**Fig. 3 Wound healing in cats at 24 days after experimental skin lesions: wound closure with hydrogel (Fig. 3a) is significantly slower compared to those treated with Valeoskin® (Fig. 3b)**

application techniques resulting in effective tissue concentrations with fewer systemic side effects are needed.

### Transdermal application (TDA) technology

The TDA technology we used was developed for human and veterinary applications ('MedDrop' and 'VetDrop'). The principle of this technology is based on a non-invasive, pain-free delivery of active ingredients through or onto the skin. Applications are meant for therapies of skin and also joint problems. The system has been applied successfully in human patients with a variety of skin diseases and in horses with lameness. In fact, a declared goal is the medical device registration for the human medical market and, therefore, preclinical studies in animals were and are still conducted at our institution.

The technology was developed by MedDrop Technology AG (Zürich, Switzerland) and is based on an oxygen flow through a Venturi valve as well as a computer-operated application system which produces a nanodispersion of a drug mixture in the oxygen flow (Fig. 1). Compressed oxygen is delivered through special tubing to the applicator system. The applicator is a nanodispersion device that has a drug reservoir (customised capsules). The oxygen propels the carrier vehicle and the active ingredients under pressure through the diffuser system, which is held to the skin at a distance of approximately 2cm. The combination of the oxygen and the carrier

molecule transports the active ingredients through the skin into the deeper tissues.

### TDA for skin problems

As for the skin, the TDA technology is used in deep wounds with a chitosan-based scaffold (Valeoskin®) in combination with porcine gelatin to give a vertical structure for the wound and ingrowing cells from the regenerating wound bed (Fig. 2). This scaffold is degraded into amino acids, oligopeptides and glucosamine monomers, which can be utilised for regeneration processes, thus improving cell proliferation and vascularisation within the wound bed. Together with the TDA technology, other molecules (such as NSAIDs) can further be delivered into the deeper wound areas, and thus reach areas unreachable with conventional application methods.

Ongoing experimental preclinical studies in rats and cats at the CABMM have shown that the combination of the Valeoskin scaffold and the TDA technology is far superior to conventional wound treatment, such that closure of standardised wounds is almost 50% faster compared to controls that were only treated with hydrogel alone (Fig. 3). Along the same lines, it could be shown in clinical studies with deep and chronically infected wounds in humans due to diabetic ulcers that long term wounds over several years could be closed within a few months using the TDA technology in combination with the Valeoskin scaffolds (clinical study ongoing).

### TDA for cartilage lesions

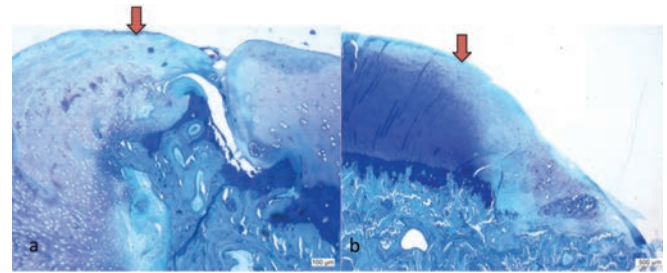
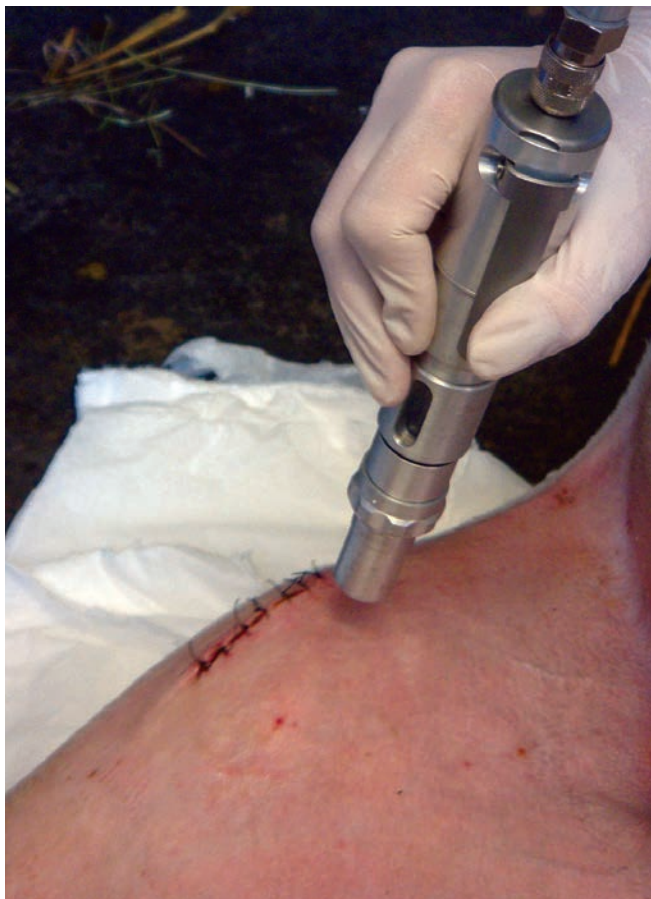For cartilage lesions, preclinical studies in sheep were conducted at the CABMM to study the regeneration potential of the TDA technology using the femoral condyles of the stifle joint as an animal model. Experimental lesions of 6mm diameter were created in the weight-bearing area of both condyles and treated with a microfracturing technique in combination with the TDA technology for post-operative treatment (Fig. 4). Several groups were formed with treatments immediately after surgery and then every two to three days for a total of 18 applications. The application area was of 10cm<sup>2</sup> over the femoral condyles. Sheep

either received the vehicle alone, vehicle plus chito-oligosaccharide, vehicle plus carprofen (ca. 6.7%), vehicle plus chito-oligosaccharides plus carprofen, or the carrier oxygen alone, and, finally as controls, carprofen at a dosage of 4mg/kg/BW given intravenously.

Blood concentrations of carprofen concentrations were measured at different time intervals from all animals, the controls and the ones where carprofen was also part of the TDA mixture. After the first treatment, concentrations were measured over 18 hours, and then six hours after each treatment up to 40 days. For the intravenous control group, concentrations were measured at several intervals for 12 hours for five days, and then at eight and 12 days after the intravenous applications of carprofen. In addition, synovial fluid measurements were conducted at weekly intervals over six weeks.

## Results

For the TDA groups, carprofen concentration could already be measured at 30 minutes after treatment with the peak concentration at 18 hours. Plasma levels increased after each application and could be well maintained over the entire 18 applications. Although lower than in blood samples, carprofen concentrations in synovial fluid correlated well with the plasma concentrations and could be measured also with the peak at six weeks. The combination with oligosaccharides increased the permeability and the concentration in the synovial fluid. Not surprisingly, the control groups had the highest peak plasma concentration of carprofen at just ten minutes after intravenous application, and also about a 300-fold higher overall concentration compared to the TDA group.



**Fig. 5 Histology picture of cartilage lesion at three months after surgery and six weeks after the last TDA application with either vehicle alone (Fig. 5a) or vehicle + carprofen as a mixture (Fig. 5b): note the adjacent cartilage (block arrow), which shows considerable loss of matrix staining when vehicle alone is applied compared to the mixture of vehicle + carprofen**

It has to be noted, however, that the carprofen concentration was higher in the classic intravenous injection than in the mixture of the TDA to begin with. Interesting was the fact that the TDA technology provided a longer lasting, steady and increasing concentration of carprofen after each application, whereas the high peaks after intravenous application decreased rather quickly and had no long-lasting effect. Although lower in concentration, with the TDA technology the local concentration was sufficient to have an improved effect on the degradation of the adjacent hyaline cartilage without having the same complication effects as seen in systemic applications.

Normally, the edges of a cartilage lesion degrade quickly and are almost acting as a 'nucleus' for degradation to spread further into the cartilage matrix – this being a major reason why cartilage degradation cannot be stopped once it has started. In our preclinical sheep experiments, it could be shown that the TDA technology using the vehicle plus chito-oligosaccharides plus carprofen combination improved the histological score of the adjacent cartilage above all other groups (Fig. 5). These results suggested that the lower intra-articular concentration of carprofen may have a more beneficial effect on maintaining a proper balance between regenerative and degenerative processes within the joint.

## Further study

Encouraged by these results, another pilot study in sheep was conducted with an animal model for chronic hyaline cartilage degradation after the creation of a subchondral bone defect in the proximal metaphyseal area of the tibia. A rectangular defect of 1.5cm width, 1.5cm height and 1.8cm depth was created at the medial aspect of the tibia plateau, just 4mm below the articular cartilage surface. The bone defect was filled with autologous bone grafts for all six animals.

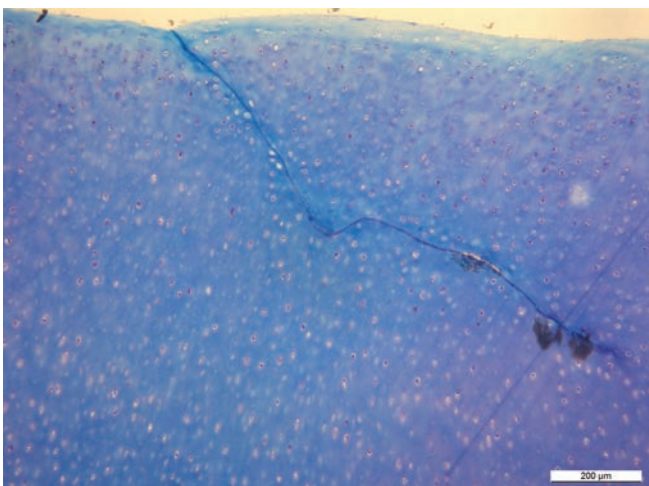
**Fig. 4 TDA application in living sheep at the medial aspect of the stifle joint**

Earlier studies performed with this animal model of 136 experimental sheep at the CABMM demonstrated severe cartilage matrix degeneration in 100% of the animals within the first two to three months, starting with severe signs of matrix damage at just two weeks after surgery. In the pilot study comparing three sheep to three untreated animals, the TDA technology was applied immediately after surgery and for daily treatments thereafter until sacrifice of the animals at two weeks. This time, the TDA mixture for the active ingredients consisted of vehicle plus chito-oligosaccharides plus Diclofenac instead of carprofen (another NSAID).

Our earlier findings with the effect of TDA technology to prevent damage to the adjacent cartilage could be confirmed: the three animals treated with vehicle plus chito-oligosaccharides plus Diclofenac showed better cartilage surface preservation compared to the untreated animals, where fibrillation and cleft formation was readily visible. Overall proteoglycan loss was clearly less severe, indicated by improved matrix staining using toluidine blue. Interestingly, small clefts were also seen which, in contrast to the control groups, were still 'glued' together and where the edges were still filled with viable cells as if in an attempt to heal the lesion (Fig. 6). Clefts in cartilage surfaces are normally wide open and do not grow back together. In addition, more viable chondrocytes were seen in the TDA-treated cartilage samples compared to the untreated controls, which only received autografts to fill the bone defect.

Our hypothesis at this point is that the TDA treatments may have several positive effects on cartilage preservation: the relatively low

**Fig. 6 Histology picture of hyaline cartilage after creating a subchondral metaphyseal defect in the proximal tibia: note that the cleft in the cartilage, which is a common sign for cartilage degeneration, is still sealed together. In addition, no loss of cellular viability or loss of metachromatic staining of the matrix is noted close to the cleft after TDA application**



### Additional authors

Michèle Sidler, Dr med vet, PhD, and Nathalie Fouché, Dr med vet, Musculoskeletal Research Unit (MSRU);

Peter Kronen, Dr med vet, Dipl ECVA, DVM, and Katja Nuss, Dr med vet, MSRU and Small Animal Surgery Department, CABMM;

Claudio Venzin, Vetsuisse Faculty ZH, University of Zurich, Switzerland; and

Friedrich von Hahn, MedDrop Technology AG, Mühlebachstrasse 72, 8008 Zurich, Switzerland.

concentration of the NSAIDs may just be enough to inhibit cartilage degradation locally while not interfering with the regenerative processes and required increase of macromolecule synthesis to maintain the homeostasis of the matrix. In addition, oxygen as the carrier system may beneficially influence chondrocyte viability and proliferation at the same time. Further studies are ongoing where optimal concentrations of the active ingredients and long term effects are tested in the same animal model.

### Outlook

The TDA technology is a promising tool for the transcutaneous delivery of active ingredients to deeper layers of tissue which in disease may not be amenable to classic ways of medication. Future studies at the CABMM will investigate the possibility of modulating regenerative and inflammatory processes with this type of regimen in wound and cartilage regeneration.

### References

- 1 Roland Schubotz: Der Einfluss eines definierten Defektes im subchondralen Knochen auf den darüberliegenden Knorpel (thesis accepted, December 2008)
- 2 Nathalie Fouché: Konzentrationsanalysen und pharmakokinetische Betrachtungen transdermaler Applikation von Carprofen mit Hilfe einer neuartigen Applikationstechnik (thesis accepted September 2012)
- 3 Sidler Michèle, Nathalie Fouché, Ingmar Meth, Friedrich von Hahn, Brigitte von Rechenberg and Peter W Kronen (2013): Transcutaneous Treatment with Vetdrop® Sustains the Adjacent Cartilage in a Microfracturing Joint Defect Model in Sheep. *The Open Orthopedics Journal*, 7, 57-66. DOI: 10.2174/1874325001307010057
- 4 Sidler Michèle, Nathalie Fouché, Ingmar Meth, Friedrich von Hahn, Brigitte von Rechenberg, Peter W Kronen (2014): Preliminary study on carprofen concentration measurements after transcutaneous treatment with Vetdrop® in a microfracture joint defect model in sheep. *BMC Veterinary Research*, 10.268. doi:10.1186/s12917-014-0268-6

HORIZON 2020

**Brigitte von Rechenberg**  
 Prof Dr med vet, Dipl ECVS  
 Musculoskeletal Research Unit (MSRU)  
 Small Animal Surgery Department  
 The Competence Center for Applied Biotechnology  
 and Molecular Medicine (CABMM)

<http://www.cabmm.uzh.ch/index.html>  
[http://www.vet.uzh.ch/index\\_en.html](http://www.vet.uzh.ch/index_en.html)